

# Orbicularis Suspension Flap and Its Effect on Lower Eyelid Position

## A Digital Image Analysis

Christopher I. Zoumalan, MD; Jessica Lattman, MD; Richard A. Zoumalan, MD; David B. Rosenberg, MD

**Objective:** To evaluate changes in lower eyelid position using digital image analysis in patients who have undergone an orbicularis suspension flap combined with blepharoplasty.

**Methods:** A total of 68 patients (136 eyes) underwent a lower eyelid orbicularis oculi suspension flap combined with blepharoplasty. Digital image analysis was used to standardize each patient's preoperative and postoperative photographs for accurate objective comparison. The photographs were analyzed for lower eyelid position.

**Results:** The mean (SD) preoperative standardized distance from the center of the pupil to the lower eyelid margin (MRD2) in all procedures was 5.53 (0.74) mm. The

mean (SD) postoperative standardized MRD2 was 5.22 (1.0) mm. There was a statistically significant difference in MRD2 position such that the postoperative MRD2 position decreased or the lower eyelid position was elevated by an average of 0.31 mm in comparison to the preoperative position ( $P < .001$ ).

**Conclusions:** A well-performed suspension flap can elevate the lower eyelid position to a more natural and anatomically appropriate position. By resuspending the ptotic orbicularis muscle, the suspension flap also reinforces the underlying attenuated orbital septum. Such cases may not achieve the optimum level of rejuvenation if isolated lower eyelid blepharoplasty is performed.

*Arch Facial Plast Surg.* 2010;12(1):24-29

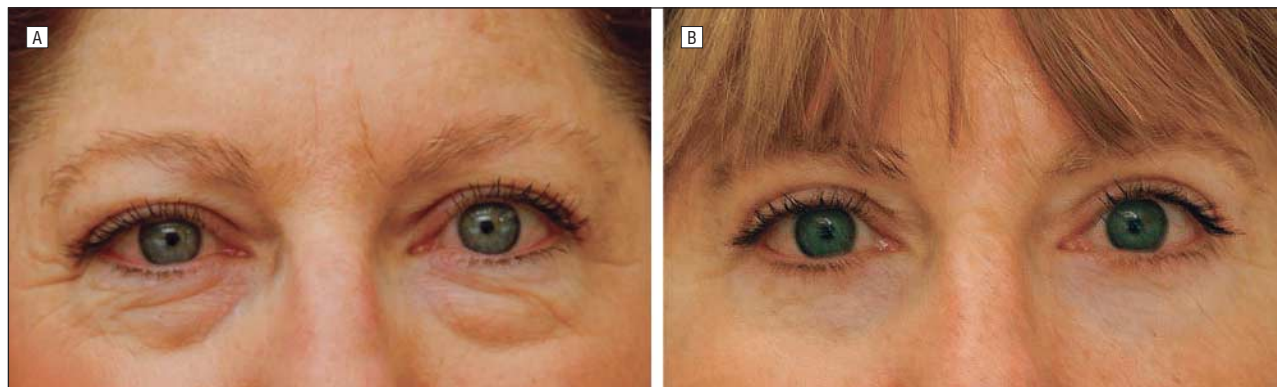**Author Affiliations:** Division of Ophthalmic Plastic and Reconstructive Surgery, Department of Ophthalmology (Drs C. I. Zoumalan and Lattman), and Division of Facial Plastic and Reconstructive Surgery, Department of Otolaryngology–Head and Neck Surgery (Drs R. A. Zoumalan and Rosenberg), Manhattan Eye, Ear, and Throat Hospital, and Division of Ophthalmic Plastic and Reconstructive Surgery, Department of Ophthalmology, New York University School of Medicine (Dr C. I. Zoumalan), New York, New York.

**T**HE LOWER EYELIDS ARE PARTICULARLY susceptible to the effects of aging, which include increased skin laxity, loss of ligamentous support, and septal attenuation with subsequent orbital fat prolapse. Furthermore, aging also affects the lower orbicularis oculi muscles, which can become atonic and ptotic.<sup>1,2</sup> In patients with considerable lower eyelid skin excess with inferior rim hollowing, traditional transcutaneous or transconjunctival blepharoplasty alone may not achieve optimal rejuvenation. In fact, excessive removal of herniated orbital fat through a blepharoplasty incision can often exacerbate the hollow appearance. The orbicularis muscle suspension flap is a useful technique that can be used in these selected cases in combination with current blepharoplasty techniques.

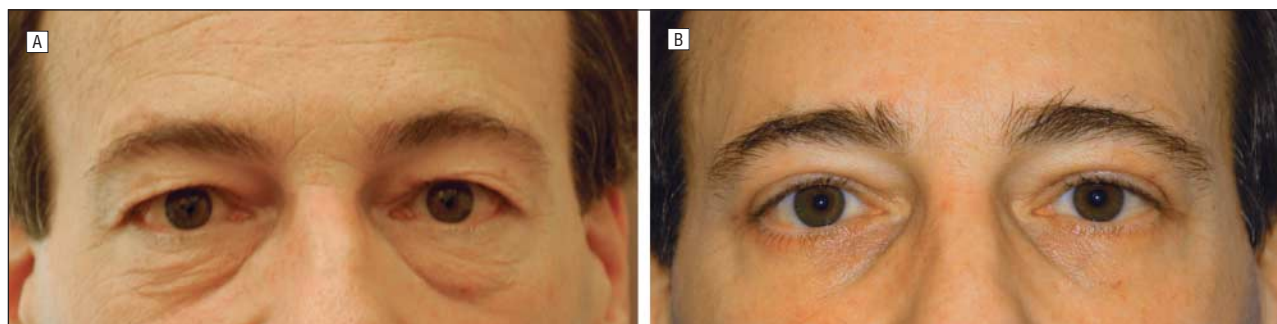However, creating an orbicularis suspension flap requires a transcutaneous incision, an approach that is well known to have a higher rate of eyelid retraction and malposition than transconjunctival blepharoplasty.<sup>3-7</sup> Cicatricial changes from vio-

lation of the anterior and middle lamellae are largely responsible for such complications. Rosenberg et al<sup>8</sup> previously reported that the “inside-out” technique, which combines a transconjunctival and transcutaneous approach to blepharoplasty, is a safe alternative to traditional transcutaneous incision. They reported no postoperative changes in lower eyelid position or canthal integrity in patients who underwent the combined inside-out technique.

We believe that resuspending the orbicularis muscle not only aids in rejuvenating the lower lid but also increases lower eyelid support and further helps to prevent postoperative eyelid malposition. This technique has been described in prior literature but never quantified.<sup>2,9</sup> Of importance, the use of digital image analysis has recently been used in assessing postoperative lower eyelid position in blepharoplasty.<sup>8,10</sup> Using digital image analysis, we aim to directly evaluate the changes in lower eyelid position after an orbicularis suspension flap is performed in selected cases involving lower eyelid aging effects. To our knowledge, the objective



**Figure 1.** Photographs of a female patient before and after lower eyelid surgery. A, Preoperative photograph of a woman with a significant amount of redundant skin, orbicularis ptosis, and moderate amounts of prolapsed fat. B, The same patient 1 year after undergoing orbicularis suspension and "inside-out" blepharoplasty.



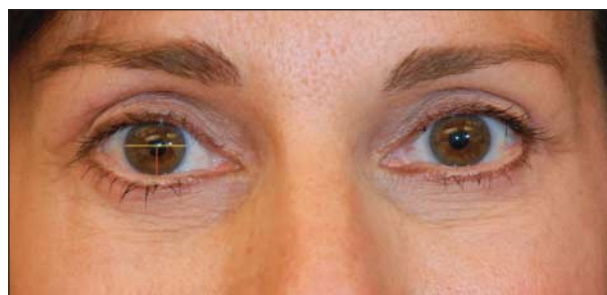**Figure 2.** Photographs of a male patient before and after lower eyelid surgery. A, Preoperative photograph of a man with a significant amount of redundant skin, mild prolapsed fat, and orbicularis ptosis. B, The same patient 8 months after undergoing orbicularis suspension and "inside-out" blepharoplasty.

evaluation of postsurgical changes after such an operation has never been performed.

## METHODS

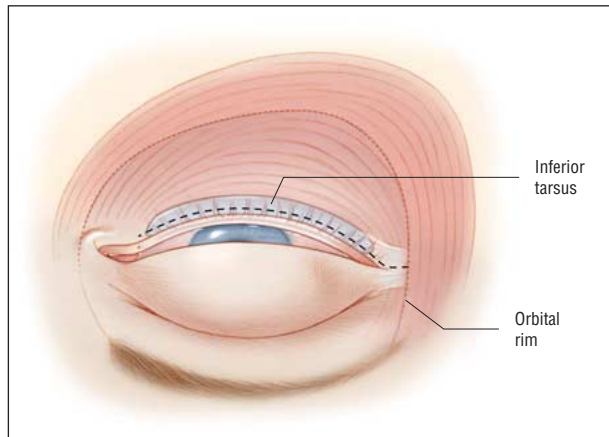
A retrospective medical record review, which was performed in all cases involving patients who were seen by the senior author (D.B.R.) from 2007 to 2008, identified 68 patients (136 eyes) who had undergone lower eyelid orbicularis oculi suspension flap in combination with an inside-out blepharoplasty. Patients who underwent an orbicularis suspension flap had complex lower eyelid aging effects that consisted of any combination of the following: significant lower eyelid skin excess, significant orbital fat prolapse, lower eyelid orbicularis muscle ptosis, or inferior rim hollowing (**Figures 1, 2, and 3**). The exclusion criterion was a history of blepharoplasty or eyelid malposition surgery (ie, ectropion or entropion repair). In such instances, the orbicularis oculi vascular supply, the lower eyelid retractors' position, and septal integrity could be compromised. To maximize the vascular supply to the orbicularis flap, smokers were encouraged to undergo a 2-week moratorium before and after surgery. Concomitant chemical peels or laser resurfacing was not performed in our study patients.

All patients underwent preoperative and postoperative evaluations. Medical history included prior treatment for dry eyes; use of eyedrops or other medications; prior eyelid surgery, including LASIK (laser in situ keratomileusis); symptoms of dry eye; and existence of medical conditions predisposing to dry eyes. Examination was performed to evaluate the tear film, eyelid malposition (ie, ectropion or entropion), lagophthalmos and Bell phenomenon, degree of eyelid laxity, amount of skin excess, and degree of orbital fat prolapse. Eyelid laxity was evaluated by the snap test



**Figure 3.** Digital image analysis was used to standardize preoperative and postoperative external photographs. The distance (pixels) from the light reflex to the lower eyelid margin (MRD2, red line) and the corneal diameter (yellow line) were measured. The lower eyelid margin was then standardized to an average horizontal corneal diameter.

(the rate that the lower eyelid returned to the normal position when it was pulled away from the globe) and the distraction test. Patients with canthal laxity requiring a lateral canthal shortening procedure were excluded from the study. The amount of skin to be excised was evaluated by the pinch test and lower eyelid excursion. The degree of orbital fat prolapse was graded from absent to 4+ along the medial, central, and temporal compartments in primary gaze and upgaze with and without retropulsion of the globes. Standardized preoperative and postoperative blepharoplasty photographs were taken, including a frontal view in neutral gaze, with eyes closed, an upward gaze, and corresponding lateral views. Photographs were taken with a digital camera (Cybershot DSC-F828; Sony Electronics Inc, Tokyo, Japan) with a macrolens at a reproduction ratio of 1:4. Photographs were taken at a fixed distance, under identical lighting conditions, with the patient in a sitting position and with the eyes in primary gaze.



**Figure 4.** The subciliary incision site is indicated by the dashed black line (right eye). The preseptal and orbital orbicularis muscle fibers are also shown. Although the pretarsal orbicularis muscle is preserved in the procedure, it is not shown so that the underlying tarsal plate can be seen.

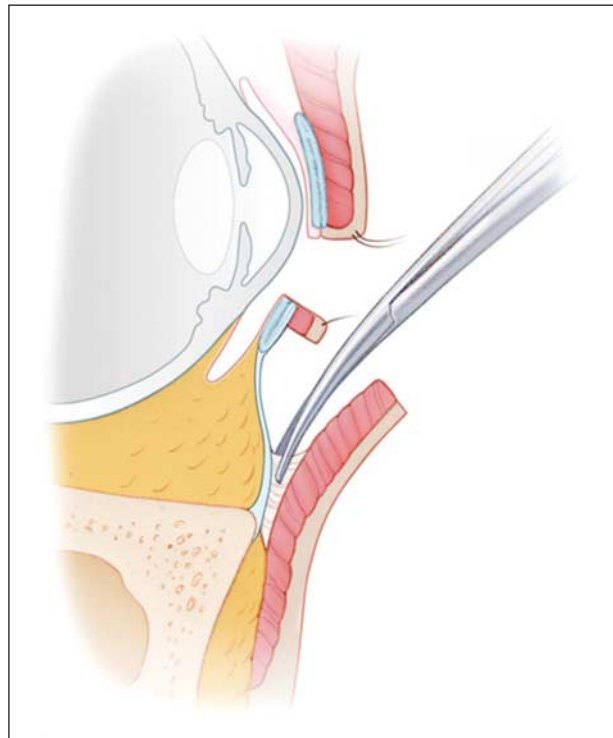
Digital image analysis was used to standardize each patient's preoperative and postoperative photographs for accurate objective comparison. Preoperative and postoperative photographs at the longest follow-up visit were analyzed for lower eyelid position. Adobe Photoshop version 7.0.1 (Adobe Systems Inc, San Jose, California) was used to measure the distance (pixels) from the center of the pupil to the lower eyelid margin (MRD2) and the corneal diameter (Figure 3). The MRD2 was then standardized to an average horizontal corneal diameter (calculated as 11.64 mm in women and 11.71 mm in men), as described previously.<sup>10,11</sup> A *t* test was used for statistical analysis.

## TECHNIQUE

All patients received general anesthesia during their procedures. Corneal shields moistened with saline were placed in each eye before surgery. A local anesthetic mixture (lidocaine, 1%, with 1:100 000 epinephrine) totaling 3 mL was injected transconjunctivally into the orbital fat as well as subcutaneously with a 30-gauge needle in all patients.

A transconjunctival approach was used to facilitate access to the fat compartments and to release the lower eyelid retractors. The lower eyelids were retracted manually by the surgeon, while a conjunctival incision was made with a guarded Colorado tip needle 1 mm below the tarsal border. The incision extended just lateral to the medial puncta to the area just medial to the lateral canthus and functioned to sever the lower eyelid retractors. A preseptal plane was dissected bluntly through the avascular tissue with a cotton-tipped applicator to the level of the orbital rim. Adequate fat was removed to allow a 1-mm smooth level of fat below the orbital rim. Fat was not repositioned. The transconjunctival incision was not closed to allow egress of fluid.

Next, a transcutaneous approach for skin removal was used in all cases. A 3-mm incision with a No. 15 blade was made just inferior and lateral to the lateral canthus following a natural lower eyelid crease. Straight iris scissors were then used to extend the subciliary incision nearly to the medial puncta (**Figure 4**). A 2- to 4-mm strip of redundant skin was then directly excised with care to preserve the underlying pretarsal orbicularis oculi. Next, the preseptal portion of the orbicularis muscle was identified, and a strip of this muscle was excised, while ensuring the preservation of the pretarsal orbicularis muscle. Monopolar cautery followed by careful dissection was used to begin the dissection of the preseptal orbicularis



**Figure 5.** The orbicularis muscle-skin flap dissection is taken inferiorly just above the inferior orbital rim. Orbicularis-retaining ligaments are preserved.

muscle from the orbital septum. This maneuver revealed the consistently observed avascular plane between the orbicularis muscle and the underlying septum. An approximate 3-mm height of pretarsal muscle was preserved and not integrated in the flap.

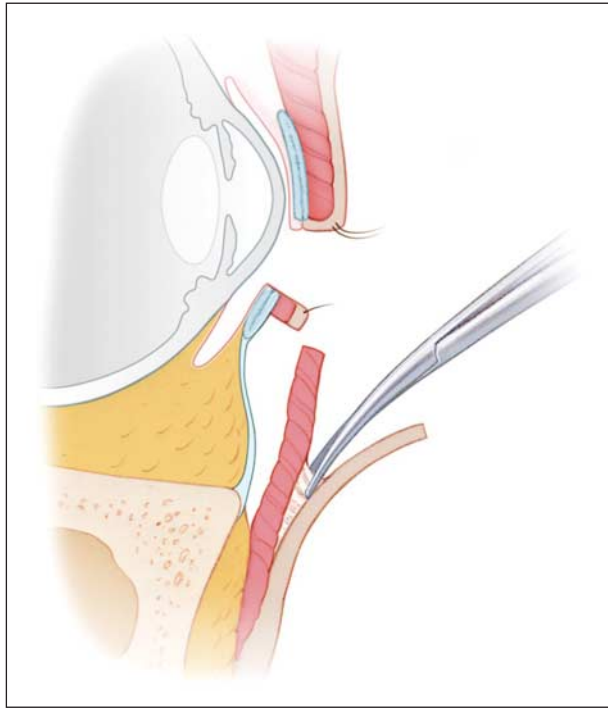
The orbicularis muscle-skin flap dissection was taken inferiorly just above the inferior orbital rim (**Figure 5**). To preserve the orbicularis innervation as best as possible, the lateral dissection did not go past the lateral orbital rim. Orbicularis-retaining ligaments were left preserved. Once the dissection was completed, the overlying skin was detached from the biplanar muscle flap in a tapered manner going from the lateral to the medial canthus (**Figure 6**).

The superior-lateral-most edge of the muscle flap was then gently grasped with a smooth forceps and lifted in a superior-lateral direction to assess the amount of suspension required for optimal lower eyelid contour (**Figure 7**). This edge was anchored approximately 2 mm below the orbital tubercle within the periosteum at the lateral orbital rim using a 5-0 clear nylon suture (**Figure 8**). Additional muscle was gently trimmed along a straight line if bunching occurred near the anchoring sutures.

For skin closure, an adequate amount of excess skin was removed such that no tension was placed during skin closure. The skin was redraped in a direction slightly medial to the vector of the muscle suspension flap so as to avoid the creation of skin pleats. A 6-0 polypropylene suture was used in a running, nonlocking fashion for skin closure. Postoperative care consisted of application of erythromycin ophthalmic ointment, ice compresses, and moisturizing tears. Sutures were removed on the fifth postoperative day. **Figure 9** depicts the steps mentioned above through intraoperative photographs.

## RESULTS

There were 68 patients (3 men and 65 women) (136 procedures) who underwent the lower eyelid orbicularis oculi



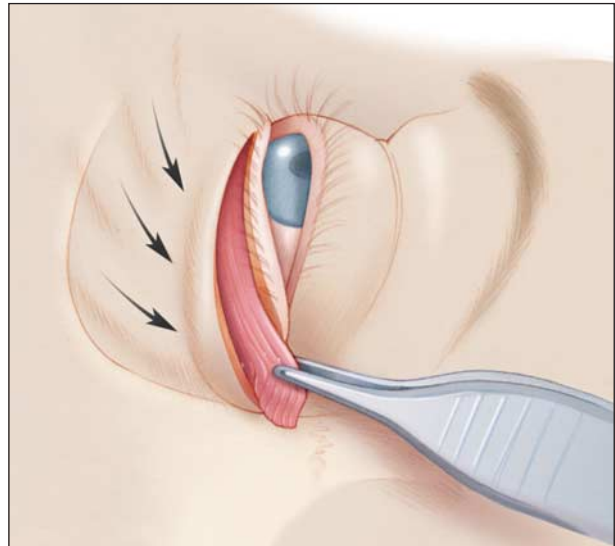
**Figure 6.** The overlying skin is detached from the biplanar muscle flap.

suspension flap in combination with an inside-out blepharoplasty. The mean patient age was 56.8 years (range, 40-72 years). In addition to lower eyelid blepharoplasty and orbicularis suspension flap, 44 patients (65%) underwent a combined upper eyelid blepharoplasty, 43 patients (63%) underwent a combined rhytidectomy, and 14 patients (21%) underwent a combined endoscopic brow-lift. The mean follow-up after surgery was 4.5 months (range, 2-18 months).

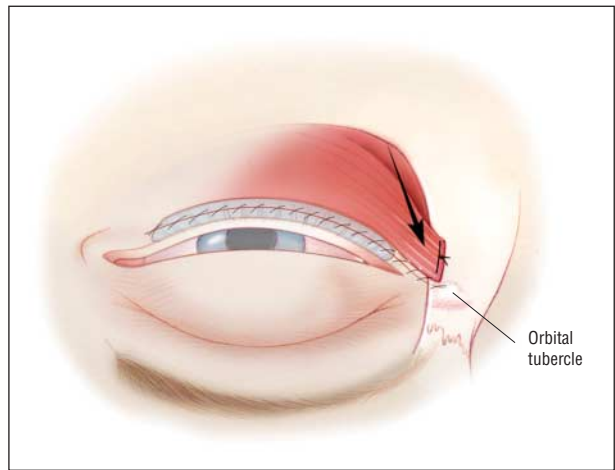
The mean (SD) preoperative standardized MRD2 for all procedures was 5.53 (0.74) mm. The mean (SD) postoperative standardized MRD2 was 5.22 (1.0) mm. There was a statistically significant difference in the MRD2 position such that the postoperative MRD2 position decreased or that the lower eyelid position was elevated by an average of 0.31 mm in comparison to the preoperative position ( $P < .001$ ).

To assess long-term postoperative results, a subgroup analysis was performed in patients who were followed up for 12 months or longer after undergoing a lower eyelid orbicularis oculi suspension flap in combination with an inside-out blepharoplasty; 8 patients (16 procedures) were identified. The mean follow-up after surgery was 14 months (range, 12-18 months). The mean preoperative standardized MRD2 for all procedures was 5.78 (0.83) mm. The mean postoperative standardized MRD2 was 4.96 (0.52) mm. There was a statistically significant difference in MRD2 position such that the postoperative MRD2 position decreased or that the lower eyelid position was elevated by an average of 0.82 mm in comparison to the preoperative position ( $P < .001$ ).

No patients had any complications of lower eyelid retraction, ectropion, hematoma, infection, or cicatricial changes. No patient underwent reoperation for any rea-



**Figure 7.** The superior-lateral-most edge of the muscle flap is grasped with a smooth forceps and lifted in a superior-lateral direction to assess the amount of suspension required for optimal lower eyelid contour.

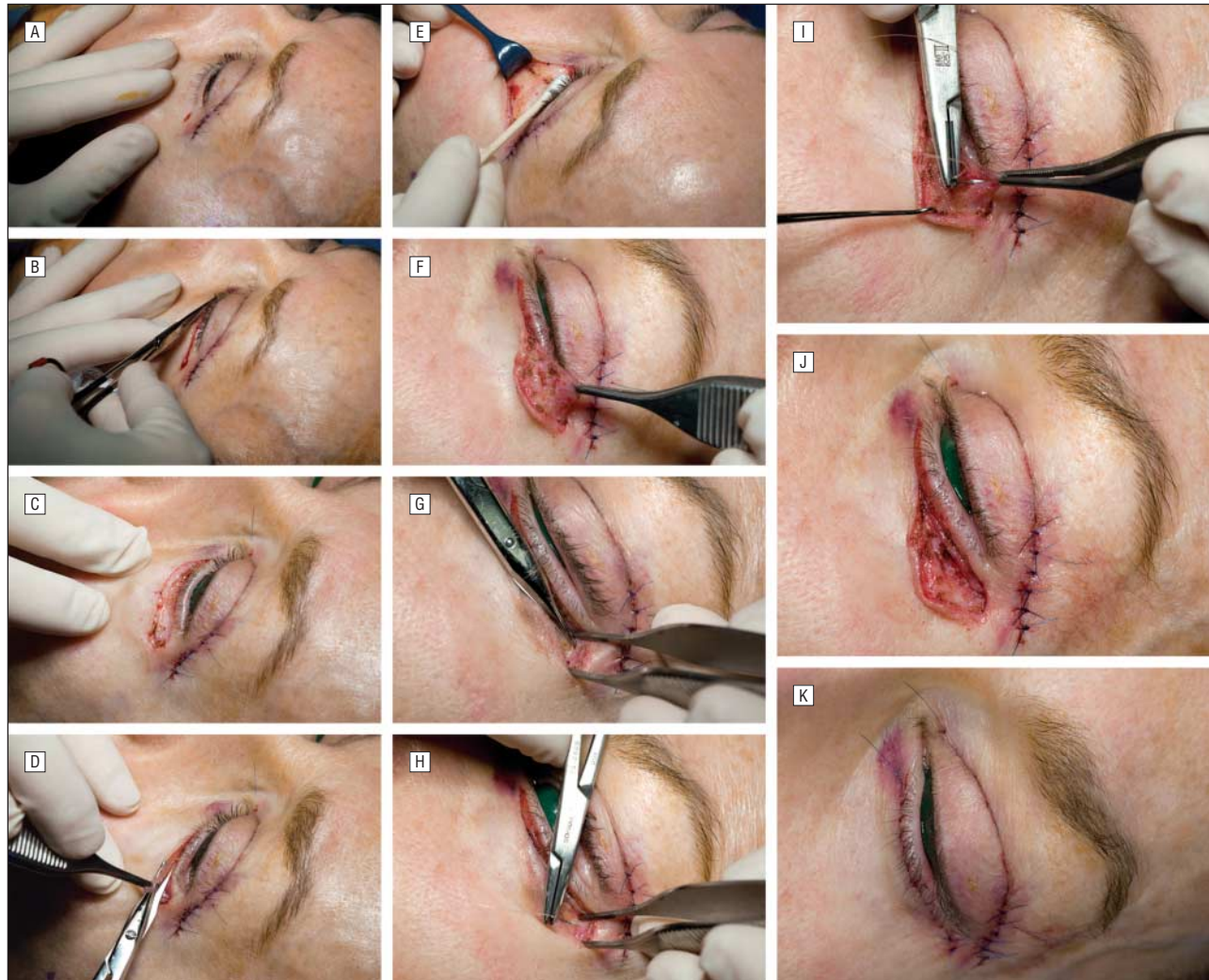

**Figure 8.** The orbicularis muscle flap is anchored approximately 1 mm below the orbital tubercle within the periosteum at the lateral orbital rim.

son. Four of 68 patients (6%) had transient chemosis, which resolved by 3 weeks after a trial of heavy ocular lubrication with the patients using preservative-free artificial tears every 2 hours while awake.

#### COMMENT

Canthal integrity, muscular dynamics, and tonicity play important roles in lower eyelid position. A reciprocal relationship occurs between the lower eyelid retractors and the orbicularis oculi muscles such that when the globe infraducts, the lower eyelid retractor muscles contract, while the orbicularis muscles relax. In contrast, when the globe supraducts (ie, Bell phenomenon), the orbicularis muscles contract, while the lower eyelid retractors relax. However, in cases of orbicularis oculi weakness, the inferior retractors are met with little antagonistic action and, in combination with gravitational effects, the lower eyelid can present with ptosis.



**Figure 9.** Montage intraoperative photographs illustrating the orbicularis suspension flap at various steps. A, A lateral canthal skin incision is made along a natural crease line. B, A subciliary incision is created. C, The preseptal and pretarsal orbicularis muscle is exposed. D, A segment of the preseptal orbicularis muscles is exposed, while the pretarsal portion is preserved. E, The underlying orbital septum is also preserved. F, The biplanar orbicularis flap is created by dissecting it from the overlying skin layer. G, Blunt dissection is performed to expose the orbital rim just inferior-temporal to the orbital tubercle. H, The suture is passed through the orbital rim. I, Then, the suture is passed through the superior-temporal portion of the orbicularis muscle flap. J, Redundant skin is carefully removed. K, Skin is closed with running polypropylene suture.

The orbicularis suspension flap provides dramatic rejuvenation in select cases of lower eyelid defects. It resuspends the age-related ptosis of the orbicularis muscles, and it helps reinforce the underlying attenuation of the orbital septum, which results in orbital fat prolapse.<sup>2,9</sup> As a result, there is a dramatic reduction in the sharp demarcation of the orbit-cheek junction and orbital fat prolapse. Traditional lower eyelid blepharoplasties and lateral canthal tightening procedures may help reduce redundant skin and orbital fat prolapse, but they fail to directly reposition the lower eyelid orbicularis muscle to an anatomically and functionally normal resting tone.

Prior studies using digital image analysis showed no significant change in lower eyelid position after transconjunctival blepharoplasty alone.<sup>8,10</sup> These results suggest that transecting lower eyelid retractors maintains lower eyelid position. In contrast, we found that performing an orbicularis suspension flap in addition to releasing the lower eyelid retractors elevated the lower eyelid position (MRD2) by approximately 0.3 mm among all patients in our study.

We believe that transecting the lower eyelid retractors allows the resuspended orbicularis flap to be met with little antagonistic action and, as a result, provides an elevated eyelid position. Furthermore, orbicularis suspension flaps aid in securing the underlying attenuated septum. By advancing the flap superiorly, the septum is secured more posteriorly, thus retroplacing the orbital fat. Though not quantifiable, our experience has shown that less herniated orbital fat needs to be removed once an orbicularis suspension flap is performed.

There seemed to be no complications and cicatricial lower eyelid changes noted in the patients who were followed up for longer than 12 months after surgery. Although this particular subgroup was small (n=8), there was a statistically significant elevation of the lower eyelid position in these patients when they were compared with all 68 patients. Also, although we did not identify any complications or lower eyelid malpositions in our selected patients, long-term complications may still present years later, and our study is unable to provide such long-term data.

Various techniques for preparing and securing the orbicularis flap have been described in the literature, and they all essentially follow the principle of superficial musculoaponeurotic system resection plication in rhytidectomies. Most of them involve muscle suture suspension and plication onto the lateral orbital rim. Wheeler<sup>12</sup> first reported on the use of an orbicularis suspension flap in the repair of involutional entropion. First reports of suspension flaps mainly involved skin-muscle flaps.<sup>9,13</sup> Other clinicians began to incorporate an orbicularis muscle flap that was superotemporally directed, with the overlying skin placed in a more medial vector.<sup>2,14,15</sup> Surgeons have also adopted the orbicularis suspension in rhytidectomies. Several authors describe the significant improvement in lower eyelid rejuvenation during a composite rhytidectomy by including the orbicularis muscle in the deep plane dissection<sup>16,17</sup>

Careful surgical dissection is necessary to maintain the integrity of the orbicularis muscle during surgery. The differences in embryological origin between the orbicularis oculi and the orbital septum may account for the surgical plane that is observed between the 2 structures during surgical dissection.<sup>18</sup> Most of the connective tissue of the upper and lower eyelids is derived from the frontonasal and maxillary processes of the neural crest cells. These processes include most of the bones, cartilage, and connective tissue, including the tarsus and the orbital septum. However, the orbicularis oculi and the rest of the facial musculature develop from the mesenchyme of the second visceral arch.<sup>19</sup>

In conclusion, techniques for lower eyelid rejuvenation vary depending on the pathogenesis of the lower eyelid defect. Many surgeons do not fully appreciate the benefits that a muscle suspension flap can offer in the treatment of age-related orbicularis ptosis. Orbicularis muscle suspension flaps can provide a dramatic rejuvenation in the lower eyelid's contour, especially when there is some degree of inferior rim hollowing. A well-performed suspension flap may also elevate the lower eyelid position and significantly reduce the risk of postoperative eyelid malposition, which is often encountered in traditional transcutaneous blepharoplasties. Such cases may not achieve the level of rejuvenation if isolated lower eyelid blepharoplasty is performed.

**Accepted for Publication:** August 27, 2009.

**Correspondence:** Christopher I. Zoumalan, MD, Division of Ophthalmic Plastic and Reconstructive Surgery, Department of Ophthalmology, New York University School of Medicine, 462 First Ave, NBV 5N 18, New York, NY 10016 (czoumalan@gmail.com).

**Author Contributions:** *Study concept and design:* C. I. Zoumalan, Lattman, R. A. Zoumalan, and Rosenberg. *Acquisition of data:* C. I. Zoumalan and Rosenberg. *Analysis and interpretation of data:* C. I. Zoumalan, R. A. Zoumalan, and Rosenberg. *Drafting of the manuscript:* C. I. Zoumalan, R. A. Zoumalan, and Rosenberg. *Critical revision of the manuscript for important intellectual content:* C. I. Zoumalan, Lattman, R. A. Zoumalan, and Rosenberg. *Statistical analysis:* C. I. Zoumalan, Lattman, R. A. Zoumalan, and Rosenberg. *Obtained funding:* C. I. Zoumalan. *Administrative, technical, and material support:* C. I. Zoumalan, R. A. Zoumalan, and Rosenberg. *Study supervision:* C. I. Zoumalan, Lattman, and Rosenberg.

**Financial Disclosure:** None reported.

## REFERENCES

1. Furnas DW. Festoons of orbicularis muscle as a cause of baggy eyelids. *Plast Reconstr Surg.* 1978;61(4):540-546.
2. Carriquiry CE, Seoane OJ, Londinsky M. Orbicularis transposition flap for muscle suspension in lower blepharoplasty. *Ann Plast Surg.* 2006;57(2):138-141.
3. Seiff SR. Complications of upper and lower blepharoplasty. *Int Ophthalmol Clin.* 1992;32(4):67-77.
4. Smith B. Postsurgical complications of cosmetic blepharoplasty. *Trans Am Acad Ophthalmol Otolaryngol.* 1969;73(6):1162-1164.
5. Smith B, Nesi FA. The complications of cosmetic blepharoplasty. *Ophthalmology.* 1978;85(7, pt 1):726-729.
6. Lisman RD, Hyde K, Smith B. Complications of blepharoplasty. *Clin Plast Surg.* 1988;15(2):309-335.
7. Kikkawa DO, Kim JW. Lower-eyelid blepharoplasty. *Int Ophthalmol Clin.* 1997;37(3):163-178.
8. Rosenberg DB, Lattman J, Shah AR. Prevention of lower eyelid malposition after blepharoplasty: anatomic and technical considerations of the inside-out blepharoplasty. *Arch Facial Plast Surg.* 2007;9(6):434-438.
9. Adamson JE, McCraw JB, Carraway JH. Use of a muscle flap in lower blepharoplasty. *Plast Reconstr Surg.* 1979;63(3):359-363.
10. Taban M, Taban M, Perry JD. Lower eyelid position after transconjunctival lower blepharoplasty with versus without a skin pinch. *Ophthalm Plast Reconstr Surg.* 2008;24(1):7-9.
11. Chang EL, Bernardino CR, Rubin PA. Normalization of upper eyelid height and contour after bony decompression in thyroid-related ophthalmopathy: a digital image analysis. *Arch Ophthalmol.* 2004;122(12):1882-1885.
12. Wheeler JM. Spastic entropion correction by orbicularis transplantation. *Trans Am Ophthalmol Soc.* 1938;36:157-162.
13. Reidy JP. Swellings of eyelids. *Br J Plast Surg.* 1960;13:256-267.
14. Labandter HP. Use of the orbicularis muscle flap for complex lower lid problems: a 6-year analysis. *Plast Reconstr Surg.* 1995;96(2):346-353.
15. Mladick RA. The muscle-suspension lower blepharoplasty. *Plast Reconstr Surg.* 1979;64(2):171-175.
16. Fogli AL. Orbicularis muscleplasty and face lift: a better orbital contour. *Plast Reconstr Surg.* 1995;96(7):1560-1572.
17. Hamra ST. The zygorbicular dissection in composite rhytidectomy: an ideal mid-face plane. *Plast Reconstr Surg.* 1998;102(5):1646-1657.
18. Meyer DR, Linberg JV, Wobig JL, McCormick SA. Anatomy of the orbital septum and associated eyelid connective tissues: implications for ptosis surgery. *Ophthalm Plast Reconstr Surg.* 1991;7(2):104-113.
19. Ocular development. Cibis GW. In: *Fundamentals and Principles of Ophthalmology.* San Francisco, CA: American Academy of Ophthalmology; 2005:129-158.