

Prevention of Lower Eyelid Malposition After Blepharoplasty

Anatomic and Technical Considerations of the Inside-Out Blepharoplasty

David B. Rosenberg, MD; Jessica Lattman, MD; Anil R. Shah, MD

Objective: To determine the position of the lower eyelid and lateral canthus after release of the lower eyelid retractors with the “inside-out technique” by measuring the marginal reflex distance 2 (MRD2) and using the lateral canthal rounding scale.

Design: Retrospective analysis.

Results: Of the 171 patients who underwent inside-out blepharoplasty, 78 were followed up for 3 months. Preoperative MRD2 was 0.942 pixels. Postoperatively, the modified MRD2 was 0.903. Although the score of the modified MRD2 was found to decrease postoperatively, the de-

crease was not statistically significant ($P < .07$). The lateral rounding scale reviewed an average preoperative score of 2.04 and a postoperative score of 1.99. There was no statistical difference between pre- and postoperative observations based on a 1-tailed *t* test. No complications were reported.

Conclusion: Using photographic analysis, the study found no difference in lateral canthal shape or MRD2 before and after surgery in patients who underwent inside-out blepharoplasty.

Arch Facial Plast Surg. 2007;9(6):434-438

THE GOALS OF LOWER EYELID rejuvenation are to restore youthful contours to the face while minimizing any complications or stigmata of surgery. A central tenet of this goal is maintenance of lower eyelid position. The aesthetically pleasing lower eyelid is described as having a slight lateral elevation with little or no rounding. As part of the normal aging process, the lower eyelid may droop or round, leading to an unsightly cosmetic appearance. Aside from extraneous considerations, lower eyelid retraction can lead to serious functional morbidities such as ocular irritation, conjunctivitis, epiphora, blurred vision, and photophobia.¹

It is crucial for the facial plastic surgeon to maintain lower eyelid position to achieve satisfactory blepharoplasty results. Lower eyelid malposition may range from lateral canthal rounding to scleral show to frank ectropion. There are 2 basic surgical approaches to aesthetic rejuvenation of the lower eyelids: transcutaneous and transconjunctival. Subciliary blepharoplasty has been associated with lower eyelid retraction rates of up to 20%.²⁻⁴ Transconjunctival blepharoplasty has a much lower rate of eyelid malposition,

even with incorporation of transcutaneous skin removal or resurfacing.⁵

The factors responsible for lower eyelid position include canthal integrity, muscular dynamics, and tonicity.⁶ Typically, the lateral canthal tendon is slightly superior to the medial canthus, providing a naturally pleasing slight elevation to the lateral portion of the lower eyelid. In patients with appropriate canthal strength, muscular dynamics play a role in the prevention of lower eyelid malposition. Hypotonicity in the orbicularis oculi may lead to ectropion without resupport of the canthal tendon, as seen in patients with facial nerve paralysis.⁷ The forces responsible include a weakened orbicularis oculi superior pull, combined with the downward vector created by the inferior eyelid retractors, and gravitational pull of soft tissues of the eyelid-cheek area.

Anatomic studies have provided further insight into the anatomy and function of the lower eyelid.⁸⁻¹¹ The retractors of the lower eyelid are analogous to those of the upper eyelid. The capsulopalpebral fascia (CPF) and the inferior tarsal muscle are directly comparable to the upper eyelid retractors of the levator aponeurosis and lower eyelids. The CPF originates from the fascia of the inferior rectus

Author Affiliations: Division of Facial Plastic & Reconstructive Surgery, Department of Otolaryngology–Head and Neck Surgery (Drs Rosenberg and Shah), and the Division of Oculoplastic Surgery, Department of Ophthalmology (Dr Lattman), Manhattan Eye, Ear, & Throat Hospital, New York, New York; and the Division of Facial Plastic & Reconstructive Surgery, Department of Otolaryngology–Head and Neck Surgery, New York University School of Medicine, New York (Dr Shah).

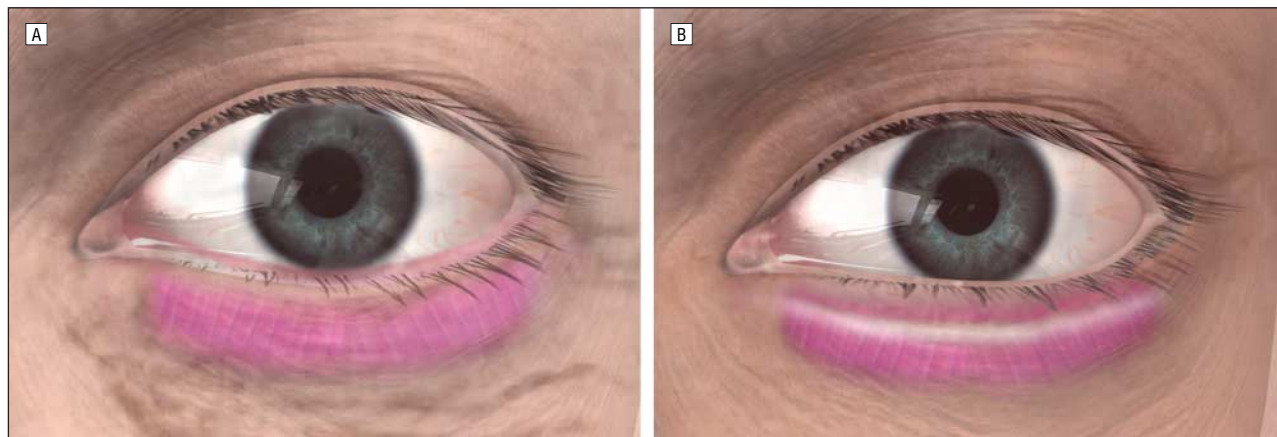


Figure 1. A, Normally the orbicularis oculi exerts a slight superior force on the lower eyelid, while the lower eyelid retractors exert a slight inferior force, mitigating a directional pull on the lower eyelid; B, after resection of the lower eyelid retractors, the orbicularis oculi exerts an unopposed superior force on the lower eyelid.

muscle and inferior oblique muscle and attaches to the inferior tarsus. The CPF pulls the lower tarsus downward, synchronized with the movement of the inferior rectus muscle. When the globe turns upward on eyelid closure (Bell phenomenon), the orbicularis oculi muscle contracts, and the inferior rectus and CPF relax. The orbicularis oculi and CPF are thought to be synchronized by reciprocal innervation, which comprises an agonist/antagonist relationship.

In upper eyelid surgery, if the levator aponeurosis, the upper eyelid retractor, is divided during upper blepharoplasty surgery, a postoperative ptosis will likely occur. During transconjunctival blepharoplasty, the lower eyelid retractors divide. Preservation of the lateral tarsal orbicularis oculi's innervation leads to an unopposed superiorly based muscular vector pull, manifesting as either maintenance or elevation of the lower eyelid (**Figure 1**). We believe that alteration of muscular dynamics plays an important role in preservation of lower eyelid position.

METHODS

A retrospective medical record review performed on the patients seen by one of us (D.B.R.) from 2002 to 2005 identified 171 patients who had undergone an inside-out transconjunctival blepharoplasty. Exclusion criteria were a history of blepharoplasty or midface procedures and having no postoperative photographs during at least 3 months' follow-up. Patients with prior blepharoplasty were excluded because of technical factors that could not be accounted for, such as preservation of orbicularis oculi supply, complete release of the lower eyelid retractors, or septal scarring.

All patients underwent a preoperative assessment of canthal integrity (snap test and eyelid distraction distance) and were screened for dry eye. Patients with canthal laxity were treated with lateral canthal shortening procedures and were excluded from this study.

Standardized blepharoplasty photographs were taken, including a frontal view in neutral gaze, with eyes closed, an upward gaze, and corresponding lateral views. Photographs were taken with a Sony Cybershot DSC-F828 camera (Sony Electronics Inc, Tokyo, Japan) with a macrolens at a reproduction ratio of 1:4.

Photographs were taken before and 6 months after surgery. Photographs were examined at 6 months by comparison of modified marginal reflex distance 2 (MRD2) and any physical signs of lower eyelid malposition (rounding, increased scleral show, or frank ectropion). Modified MRD2 was measured on all preoperative photographs as were any signs of lower eyelid malposition. Modified MRD2 is the measure of the light reflection in primary gaze to the lower eyelid lash line. The lash line was used rather than the eyelid margin to better account for eyelid eversion (**Figure 2**). A standardizing multiplier was created to compare pre- and postoperative photographs by using the fixed point of the interpupillary distance. Measurements were made with the measure tool on Adobe Photoshop 7.0 (Adobe Systems Inc, Santa Clara, California).

A scale was created to measure lateral canthal rounding (**Table**). Authors were blinded to preoperative or postoperative photographs and each eye was graded. In addition, a postoperative physical examination was performed to determine the mobility of the lower eyelid structures and formation of a cicatrix. Statistics were analyzed with the 1-tailed *t* test and values were considered significant at $P < .05$.

TECHNIQUE: THE INSIDE-OUT BLEPHAROPLASTY

In the preoperative holding area, significant fat herniation in patients was identified. All procedures were performed with the patient under general anesthesia. Corneal shields with bacitracin ophthalmic were placed during the surgery. A local anesthetic mixture (lidocaine, 1%, with 1:100 000 epinephrine on a 30-gauge needle) was injected into the lower eyelid conjunctiva in all patients and in a transcutaneous location if skin removal was planned.

THE "IN"

A transconjunctival approach was used to facilitate access to the fat compartments and release the lower eyelid retractors. The lower eyelids were retracted with a sharp double-pronged retractor. An incision was made with a guarded Colorado tip needle 1 mm from the tarsal border along the lower eyelid conjunctiva. The incision was extended from the medial puncta to the area just medial to the lateral canthus to ensure *complete release* of the lower eyelid retractors, irrespective of the location of fat removal. A pre-septal plane was dissected bluntly in an avascular plane with a cotton-tipped applicator to the level of the orbital rim.

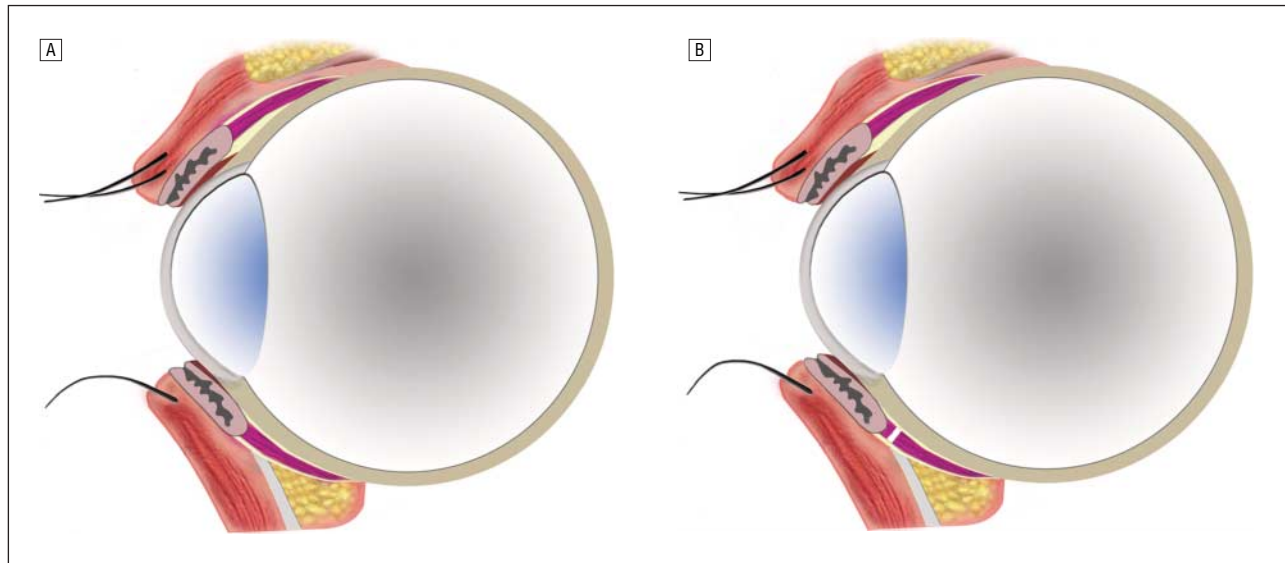


Figure 2. A, The lower eyelid retractor can be approached through a transconjunctival incision; B, with release of the transconjunctival approach, the orbicularis oculi will exert a slight superior force on the lower eyelid.

Table. Eye Rounding Scale

Score	Definition
1	No lateral canthal rounding or eversion (canthal angle acute)
2	Minimal lateral canthal rounding (canthal angle moderately enlarged with minimal rounding)
3	Moderate lateral canthal rounding with some eyelid eversion (moderate canthal angle distance with rounding)
4	Severe lateral canthal rounding (marked canthal rounding and obtuse canthal angle)

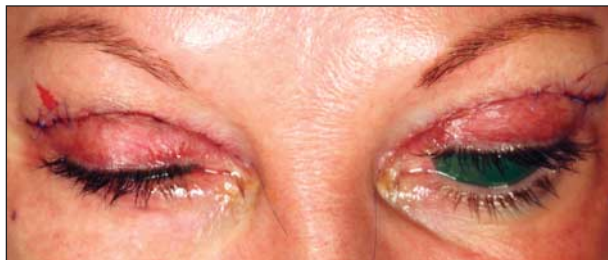

Figure 3. Immediately after resection of the lower eyelid retractors, it is evident that the lower eyelid on the right is now superior to the lower eyelid on the left.

Fat was removed only in those areas in which preoperative analysis revealed excess. The fat was removed to allow a 1-mm smooth level of fat below the orbital rim. The inferior oblique muscle was identified in all cases in which fat was removed. Fat was not repositioned and nasojugal asymmetries were addressed with fat transplantation techniques. The transconjunctival incision was not closed to allow for egress of fluid and to prevent reapproximation of the lower eyelid retractors (**Figure 3**).

THE “OUT”

A transcutaneous approach to skin removal was used in all cases. An incision with a No. 15 blade was made at the lateral border of the lower eyelid, following a lower eyelid crease. Straight Stevens scissors were used to dissect 3 mm from the border of the lower

eyelid margin to the medial puncta. The transcutaneous flap was elevated and skin was removed so that no tension was placed on the closure of the skin. A 6-0 polypropylene suture was used in a running nonlocking fashion. In instances of excessive muscular orbicularis oculi, a small portion of the septal orbicularis oculi was resected, preserving the tarsal orbicularis oculi. Postoperative care consisted of aggressive lower eyelid massage for 2 to 4 weeks to prevent cicatrix formation.

RESULTS

Of the 171 patients who underwent inside-out blepharoplasty, 78 were followed up for 3 months. Preoperative MRD2 was 0.942. Postoperatively, the modified MRD2 was 0.903 (**Figures 4, 5, and 6**).

The score of the modified MRD2 was found to decrease postoperatively but this decrease was not statistically significant ($P < .07$). Forty-three of the 171 patients had follow-up evaluations at 6 months, with no changes in modified MRD2.

The lateral rounding scale revealed an average preoperative score of 2.04 and a postoperative score of 1.99. There was no statistical difference between preoperative and postoperative observations based on a 1-tailed *t* test.

No complications were reported, including hematoma or postoperative dry eyes. Patients did not demonstrate entropion or decreased ability to look downward as a result of the lower eyelid retractors on physical examination.

COMMENT

Several technical factors in the inside-out technique warrant mentioning. The release of the retractors is complete and occurs from the medial puncta and approaches the lateral canthus of the eye. Retractor release does not typically occur with a subciliary approach with preservation of the underlying conjunctiva and associated eyelid retractors. Both a preseptal or postseptal approach will theoretically provide release of the retractors.

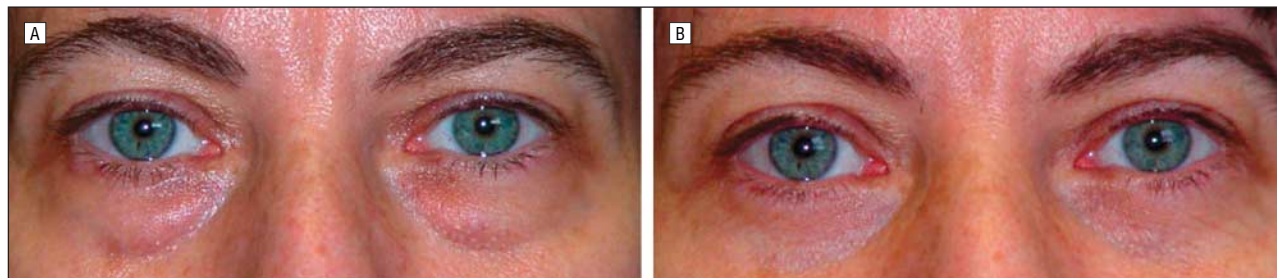


Figure 4. A, Patient seeking cosmetic rejuvenation of eyes because of excess fat and skin on lower eyelids; B, patient demonstrates maintenance of lower eyelid position. The aperture of the eye has not changed because the lateral canthal angle has not changed significantly.

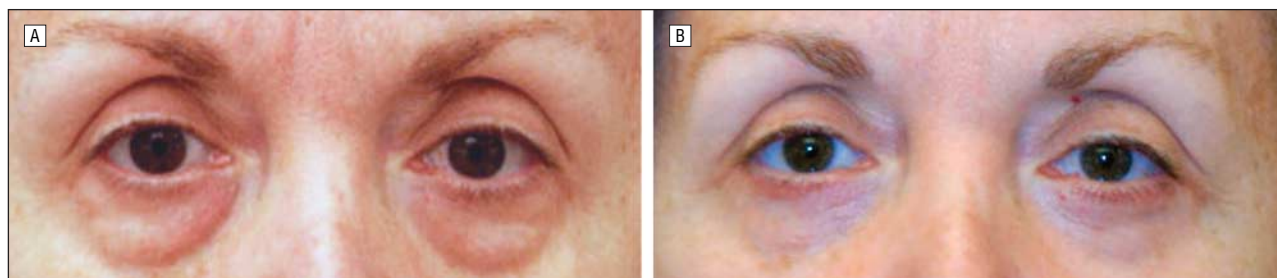


Figure 5. Patient with moderate amount of excess fat in lower eyelid compartments and excess skin. Patient demonstrates unchanged position of the lower eyelid and the aperture of the eye in preoperative (A) and postoperative (B) photographs.

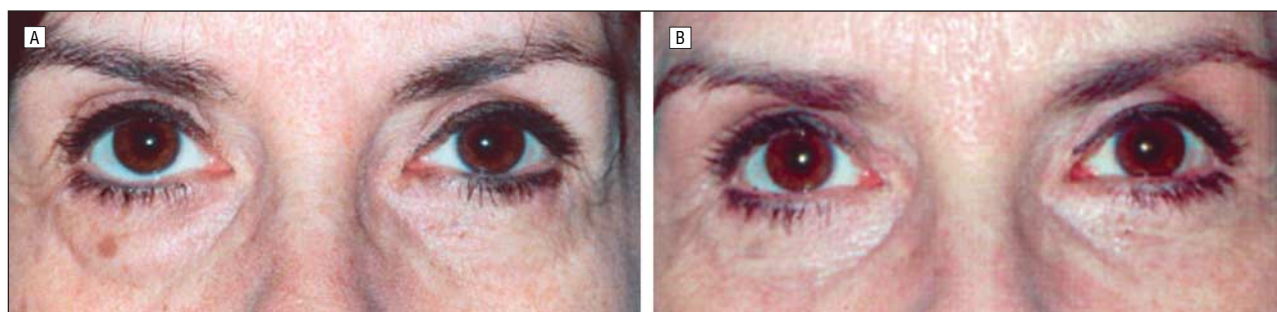


Figure 6. A, Patient with small amount of fat and excess skin seeking cosmetic changes to lower eyelids; B, patient with slight improvement of the position of the lower eyelid with minimal change to the lateral canthal angle.

A function of the lower eyelid retractors is to assist in lowering the eyelid, particularly when the inferior rectus muscle pulls the eye inferiorly. Despite this contribution to eyelid lowering, inferior gaze restriction or discomfort has not been reported after transconjunctival blepharoplasty. Our study supports the literature, with none of the patients reporting gaze restriction after release of the lower eyelid retractors.

Putterman¹² described a sole case of ectropion as a result of resection of the lower eyelid retractors. However, this case had severe lateral canthal laxity; no subsequent cases of ectropion have been reported.

Epiblepharon was reported in a subciliary approach used in an Asian patient after repair of a trimalar fracture.¹³ In Asian patients, the capsulopalpebral fascia is attenuated with weaker attachment to the tarsal plate and dermis. The incidence of epiblepharon in Asian patients is much higher because of the unopposed muscular force vector provided by the orbicularis oculi muscle. Epiblepharon has never been reported after a transconjunctival blepharoplasty. The downward effects of gravity and shortening of the middle lamellae during surgery are pos-

sible explanations for the lack of this phenomenon in patients who have undergone blepharoplasty.

DiFrancesco et al¹⁴ performed an electromyographic study on the orbicularis oculi after subciliary blepharoplasty and found that the tone and innervation were maintained after subciliary blepharoplasty. The main difference between a standard subciliary blepharoplasty and the inside-out approach is the resection of the lower eyelid retractors. While patients who have had subciliary blepharoplasty have much higher rates of lower eyelid malposition, those who have had the inside-out or the standardized transconjunctival blepharoplasty do not seem to suffer from eyelid malposition. Clearly, the transection of the lower eyelid retractors plays a role in the preservation of eyelid position in these patients.

Lateral rounding and eyelid positioning remained unchanged after surgery despite transcutaneous skin removal and trichloroacetic acid peels. Inside-out blepharoplasty offers a safe alternative to standard subciliary blepharoplasty in achieving commendable aesthetic results without compromising eyelid position or canthal integrity.

CONCLUSIONS

Maintaining the position of the lower eyelid after lower eyelid blepharoplasty is a difficult endeavor. Few studies have used objective measures to critically examine the MRD2. A lateral canthal rounding scale was developed using pre- and postoperative photographs to provide additional analysis of the lateral canthal shape or MRD2 in patients who underwent inside-out blepharoplasty.

Accepted for Publication: July 16, 2007.

Correspondence: David B. Rosenberg, MD, Department of Otolaryngology–Head and Neck Surgery, Manhattan Eye, Ear, & Throat Hospital, 115 East 61st St, New York, NY 10021 (drdavidrosenberg@aol.com).

Author Contributions: *Study concept and design:* Rosenberg, Lattman, and Shah. *Acquisition of data:* Rosenberg, Lattman, and Shah. *Analysis and interpretation of data:* Rosenberg, Lattman, and Shah. *Drafting of the manuscript:* Rosenberg, Lattman, and Shah. *Critical revision of the manuscript for important intellectual content:* Rosenberg, Lattman, and Shah. *Statistical analysis:* Rosenberg and Shah. *Obtained funding:* Lattman. *Administrative, technical, and material support:* Rosenberg, Lattman, and Shah. *Study supervision:* Rosenberg, Lattman, and Shah.

Financial Disclosure: None reported.

REFERENCES

1. Westfall CT, Shore JW, Nunery WR, Hawes MJ, Yaremchuk MJ. Operative complications of the transconjunctival inferior fornix approach. *Ophthalmology*. 1991; 98(10):1525-1528.
2. Patel PC, Sobota BT, Patel NM, Greene JS, Millman B. Comparison of transconjunctival versus subciliary approaches for orbital fractures: a review of 60 cases. *J Craniomaxillofac Trauma*. 1998;4(1):17-21.
3. Appling WD, Patrinely JR, Salzer TA. Transconjunctival approach vs subciliary skin-muscle flap approach for orbital fracture repair. *Arch Otolaryngol Head Neck Surg*. 1993;119(9):1000-1007.
4. Holtmann B, Wray RC, Little AG. A randomized comparison of four incisions for orbital fractures. *Plast Reconstr Surg*. 1981;67(6):731-737.
5. Mullins JB, Holds JB, Branham GH, Thomas JR. Complications of the transconjunctival approach: a review of 400 cases. *Arch Otolaryngol Head Neck Surg*. 1997;123(4):385-388.
6. Kakizaki H, Zako M, Nakano T, Asamoto K, Miyagawa T, Iwaki M. Three ligaments reinforce the lower eyelid. *Okajimas Folia Anat Jpn*. 2004;81(5):97-100.
7. Fedok FG, Ferraro RE. Restoration of lower eyelid support in facial paralysis. *Facial Plast Surg*. 2000;16(4):337-343.
8. Goldberg RA, Lufkin R, Farahani K, Wu JC, Jesmanowicz A, Hyde JS. Physiology of the lower eyelid retractors: tight linkage of the anterior capsulopalpebral fascia demonstrated using dynamic ultrafine surface coil MRI. *Ophthalm Plast Reconstr Surg*. 1994;10(2):87-91.
9. Hawes MJ, Dortzbach RK. The microscopic anatomy of the lower eyelid retractors. *Arch Ophthalmol*. 1982;100(8):1313-1318.
10. Lim WK, Rajendran K, Choo CT. Microscopic anatomy of the lower eyelid in Asians. *Ophthalm Plast Reconstr Surg*. 2004;20(3):207-211.
11. Wójtowicz S. Reciprocal innervation of directly and indirectly synergic and antagonistic external eye muscles. *Pol Med J*. 1966;5(3):656-661.
12. Putterman AM. Ectropion of the lower eyelid secondary to Muller's muscle-capsulopalpebral fascia detachment. *Am J Ophthalmol*. 1978;85(6):814-817.
13. Park RI, Meyer DR. Acquired lower eyelid epiblepharon. *Am J Ophthalmol*. 1996; 122(3):449-451.
14. DiFrancesco LM, Anjema CM, Codner MA, McCord CD, English J. Evaluation of conventional subciliary incision used in blepharoplasty: preoperative and postoperative videography and electromyography findings. *Plast Reconstr Surg*. 2005; 116(2):632-639.

Announcement

Visit www.archfacial.com. As an individual subscriber you can organize articles you want to bookmark using My Folder. Save links to key articles of interest and personalize the organization of My Folder using folders you create. My Folder stores links to *JAMA & Archives Journals* to which you have access and can be accessed from any of the journals.